

Epithelial ingrowth after LASIK

Category(ies): Cornea

Contributors: [Jesse Vislisel, MD](#) and Matt Ward, MD

Photographer: Brice Critser, CRA



Epithelial ingrowth occurs when the corneal epithelial cells grow within the lamellar interface beneath the LASIK flap. This may result in an inflammatory response, corneal edema, irregular astigmatism, or melting of the LASIK flap. When mild and peripheral, it may be observed. When progressive or severe, the LASIK flap must be lifted and the epithelium scraped from the bed. Recurrent cases may require suturing of the LASIK flap.

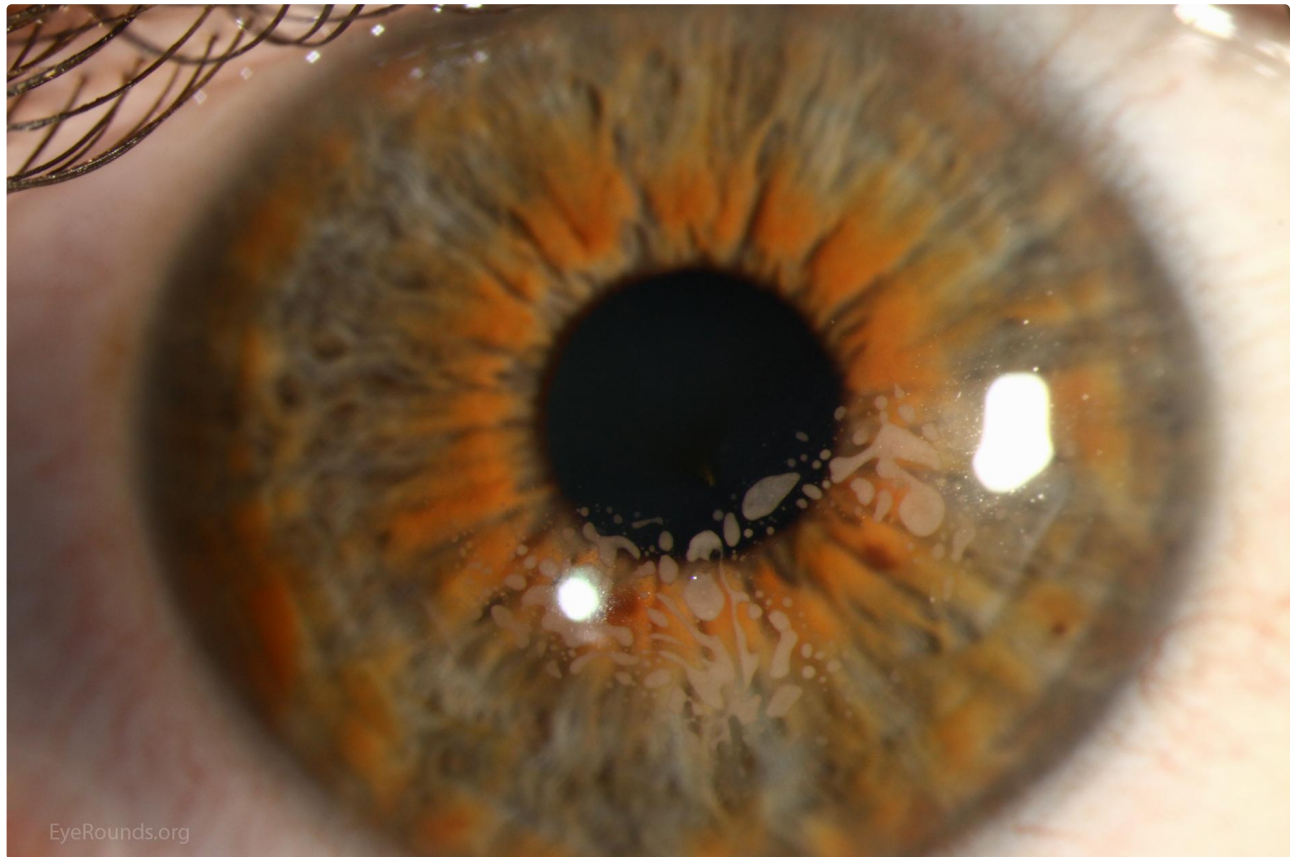

Figure 1. Nests of epithelium beneath LASIK flap

Contributor: [Jesse Vislisel, MD](#)

Nests of epithelium can be seen approaching the visual axis beneath the LASIK flap. This case occurred after microkeratome-assisted LASIK and multiple enhancement procedures

[Enlarge](#)

[Download](#)

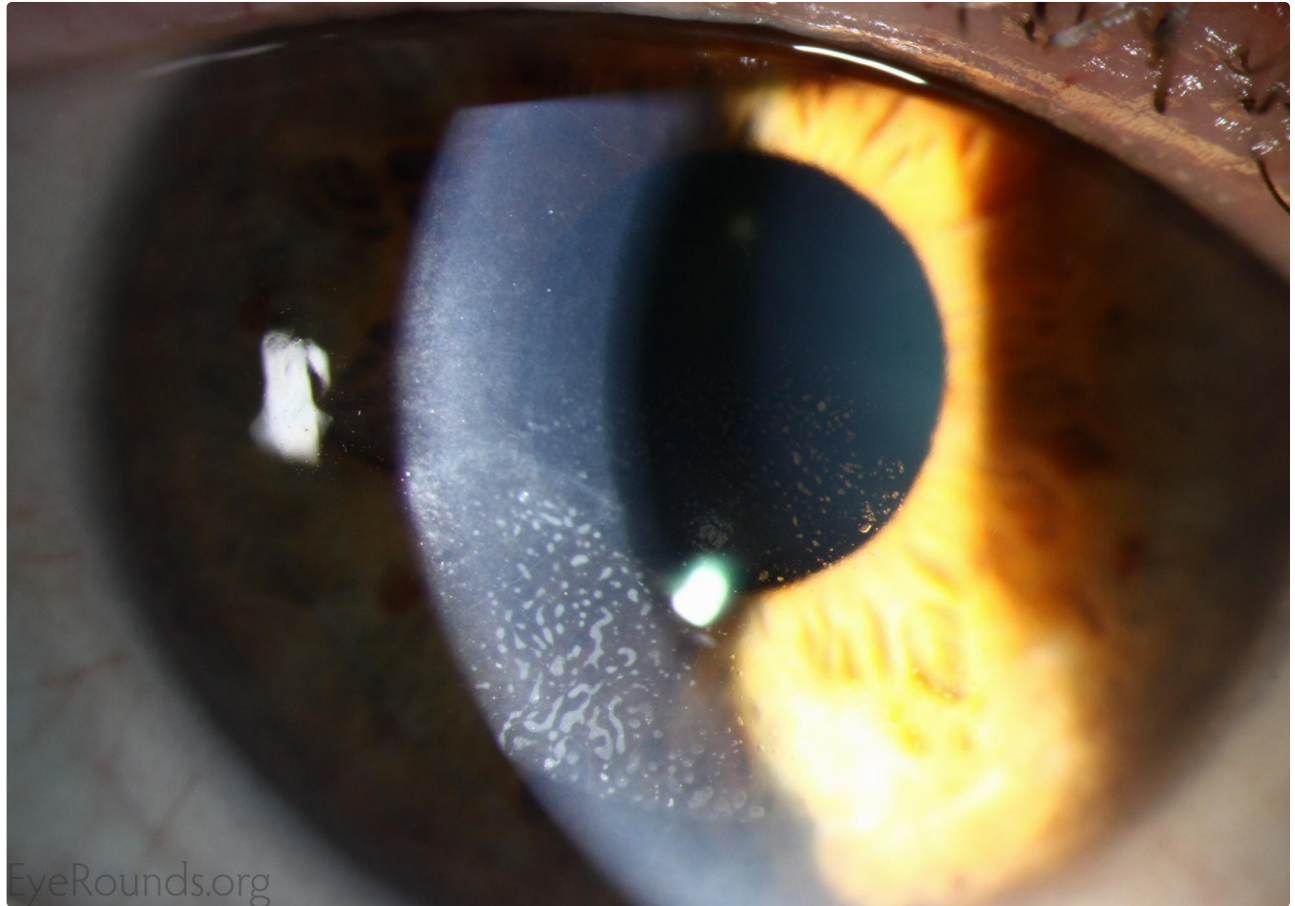


Figure 2a. Epithelial ingrowth under LASIK flap

Contributor: [Jesse Vislisel, MD](#)

Photographer: Brice Critser, CRA

Epithelial ingrowth after LASIK performed in the setting of epithelial basement membrane dystrophy. The patient developed edema of the LASIK flap and recurrent erosion syndrome, requiring lifting of the flap and removal of the epithelial ingrowth

[Enlarge](#)

[Download](#)



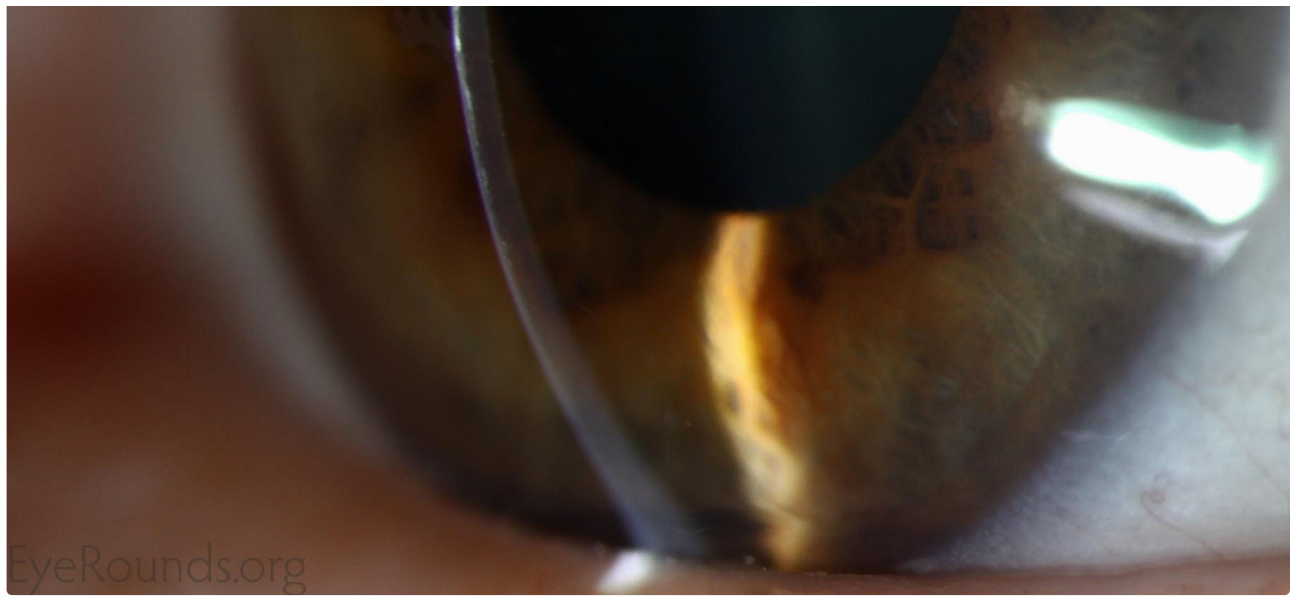


Figure 2b. Epithelial ingrowth under LASIK flap

Contributor: [Jesse Vislisel, MD](#)

Photographer: Brice Critser, CRA

[Enlarge](#)

[Download](#)

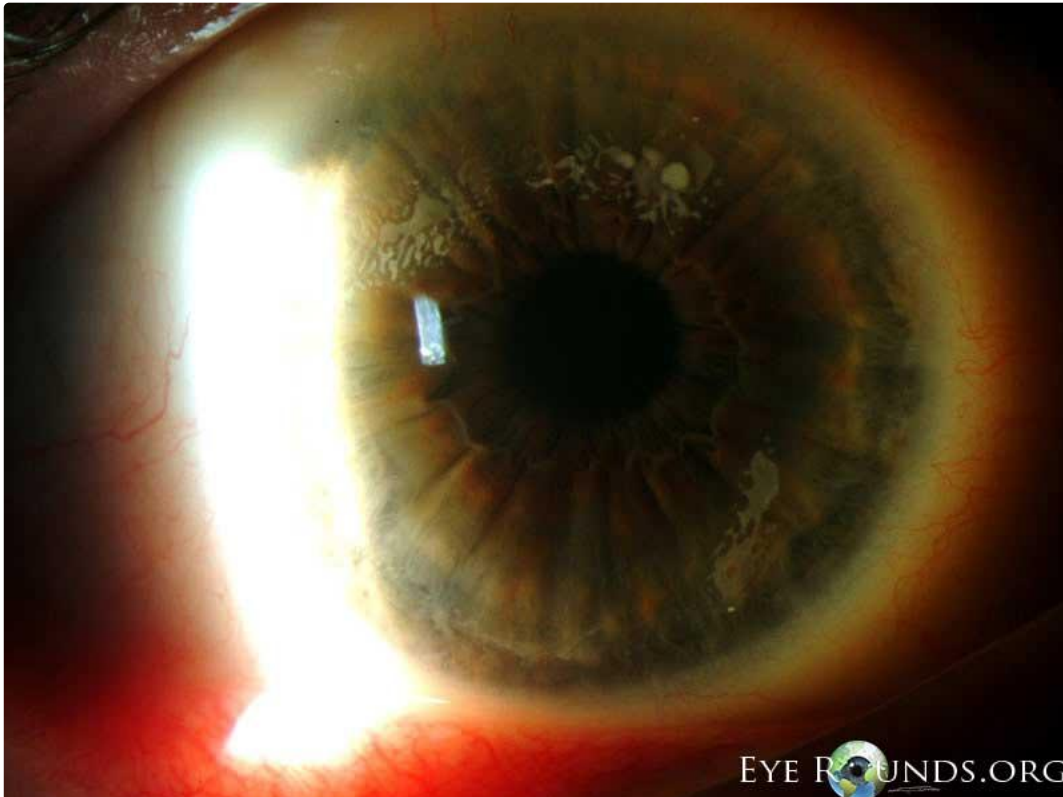


Figure 3. Epithelial ingrowth at the edges of a LASIK flap5>

Contributor: [Matt Ward, MD](#)

Epithelial ingrowth can be a vision threatening complication of LASIK surgery. If it approaches the visual axis, the flap must be lifted and the bed scraped. Recurrent ingrowth may require suturing of the flap in the location of recurrence.

[Enlarge](#)

[Download](#)

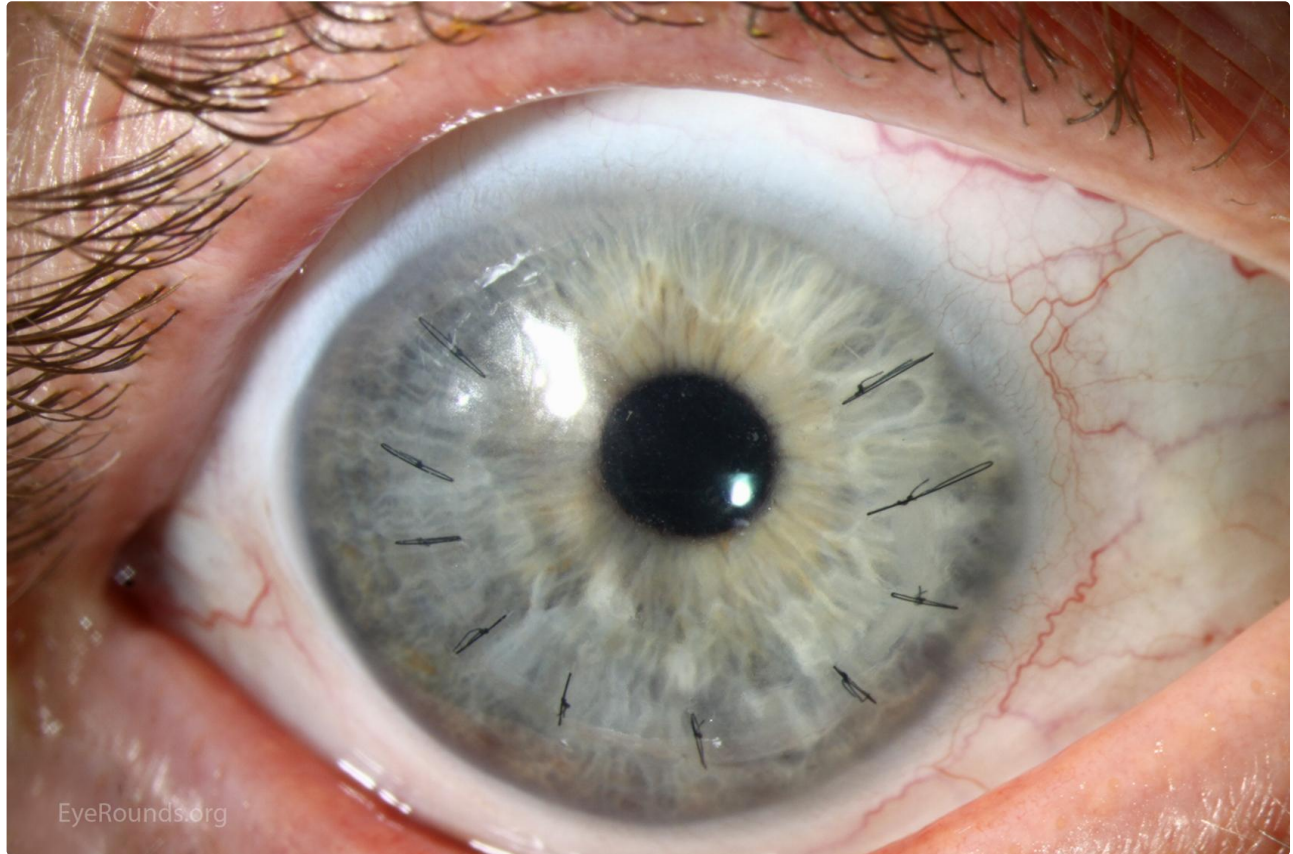

Figure 4. Postoperative Appearance

Contributor: [Jesse Vislisel, MD](#)

Photographer: [Brice Critser, CRA](#)

Postoperative appearance after lifting the LASIK flap, removing the ingrown epithelium, and suturing the flap back in place. Acuity corrected to 20/20 after the sutures were removed.

[Enlarge](#)

[Download](#)

Image Permissions:



Ophthalmic Atlas Images by [EyeRounds.org](#), [The University of Iowa](#) are licensed under a [Creative Commons Attribution-NonCommercial-NoDerivs 3.0 Unported License](#).

Address

University of Iowa
Roy J. and Lucille A. Carver College
of Medicine
Department of Ophthalmology and
Visual Sciences
200 Hawkins Drive
Iowa City, IA 52242

[Support Us](#)

Legal

Copyright © 2019 The University of
Iowa. All Rights Reserved
[Report an issue with this page](#)
[Web Privacy Policy](#) |
[Nondiscrimination Statement](#)

Related Links

[Cataract Surgery for Greenhorns](#)
[EyeTransillumination](#)
[Gonioscopy.org](#)
[Iowa Glaucoma Curriculum](#)
[Iowa Wet Lab](#)
[Patient Information](#)
[Stone Rounds](#)
[The Best Hits Bookshelf](#)

EyeRounds Social Media

Follow



Receive notification of new cases,
[sign up here](#)
[Contact Us](#)
[Submit a Suggestion](#)